

Modified Limbal Incision: An Easy and Safe Window for Extraocular Muscle Surgery

Mian M. Shafique, Nadeem H. Butt, Muhammad Khalil, Tayyaba Gul

Pak J Ophthalmol 2008, Vol. 24 No. 1

.....
See end of article for
authors affiliations

.....
Correspondence to:
Mian M. Shafique
Department of Ophthalmology
Lahore Medical & Dental
College
Lahore

Received for publication
June' 2007
.....

Purpose: To find out the advantages and disadvantages of modified limbal incision as an approach to horizontal extraocular muscles during squint surgery and its comparison with 'over the muscle' conjunctival incision.

Material and Methods: Total of 67 patients of squint were included in this prospective study which was conducted between March 1999 and October 2002. Both male and female patients of all age groups and all types of squints were included. These patients were admitted for surgery after proper assessment including history, examination and investigations. In 36 patients modified limbal incision was given in the conjunctiva (Group-I) while remaining 31 patients underwent 'over the muscle' conjunctival incision for approaching the extraocular muscles (Group-II).

Results: Approach to the extraocular muscles was easy in 94.5% cases with modified limbal incision as compared to 80.5% (25 out of 31) in over the muscle incision. No help of assistant was required for suturing of the wound during the Modified limbal approach while it was required in 59% (17/31) of cases in Group-II. Although conjunctiva was congested in good number of patients in both groups on first post op day, yet more patients were comfortable in first Group than in second group. Removal of stitches in modified limbal approach was almost non existing while in comparison stitches had to be removed in almost one third of cases in the other group.

Conclusion: Modified limbal conjunctival incision is a safe and quick approach to operate on extraocular muscles both in esotropia and exotropia, equally good for recessions and resections. Although majority of patients postoperatively have red eyes yet most of the patients are relatively more comfortable as compared to "over the muscle incision". Only two stitches are required to close the incision. Mostly there is no need to remove these stitches.

Incision and surgery have been part and parcel of each other since ages. Without an incision it was not possible to enter and deal with the tissue to be operated. As the incision healed it almost always left a scar mark which many a times was not acceptable cosmetically. For the sake of cosmetic appearance, the size of incision was reduced but at the

expense of reduced exposure of tissues under surgery. A galaxy of researchers kept on working in search of a safe and small incision till we reached the era of endoscopic surgery.

Strabismus Surgery is the ultimate answer to many varieties of squint. The commonly done procedures are recessions and resections, although advance-

ment and plication are not uncommon. All of these procedures are done on extraocular muscles. To expose extraocular muscles different conjunctival incisions are preferred^{1,2}. Commonly used approaches are limbal, paralimbal, over the muscle or fornix. Where limbal incision poses difficulty in comfortable and full exposure of extraocular muscle, 'over the muscle approach' has more post operative complications i.e. excessive scarring. So there was a need to try a special approach which provides us good exposure of extraocular muscles during surgery, has least post operative complications and is cosmetically acceptable also.

We tried a 'modified incision' at the limbus and compared its advantages and disadvantages during the squint surgery as well as postoperatively with 'over the muscle incision'.

MATERIAL AND METHODS

This study was conducted in Department of Ophthalmology Fatima Jinnah Medical College and Sir Ganga Ram Hospital, Lahore from March 1999 to October 2002. A total of 67 patients of all age groups, both sexes and all types of squint were included in the study. All the patients underwent detailed assessment including history, examination and investigations. During the surgical procedure patients were randomly divided into two groups. In 36 patients 'modified limbal incision' was given in the conjunctiva (Group-I) while remaining 31 patients underwent 'over the muscle incision' for approaching the extraocular muscles (Group-II).

The modified limbal incision comprised of a curved portion at the limbus for length of 3 clock hours just apposing the insertions site of the muscle to be tackled and two radial extensions from each end of the curved part. Each radial extension was 5mm long, one along each border of horizontal muscle. For Medial rectus of right eye the curved part was at the limbus from 1.30 o' clock to 4.30 o' clock and each radial extension from the ends of this curve was almost at right angle to the limbus as is shown in Fig 1. At the end of procedure the incision was closed by two simple interrupted stitches of 6/0 vicryl, one at

each end of curved part at the limbus i.e. 1.30 o' clock and 4.30 o' clock for medial rectus surgery of right eye. For other horizontal muscles the corresponding sites were used for incisions and stitches.

Both the incisions were closed by 6/0 vicryl interrupted stitches (Fig2). Special events like difficulty in exposing and clearing the muscles from the fascia, excessive bleeding and difficult suturing were recorded during the surgery. Each patient was followed postoperatively on first post op day, 7th post op day and at the end of one month to note any post operative problems like increased discomfort, excessive watering, lid swelling, conjunctival redness, need for re-stitching, need to remove stitches and stitch granuloma.

RESULTS

Total No of patients in the study were 67. Age of the patients ranged from 5 years to 24 years. Males and females were almost equal in number (33 vs. 34). 39 patients had esotropia while remaining 28 were suffering from exotropia. Total No of muscles tackled were 130. Recession was done on 83 muscles whereas 47 muscles were resected. Out of these 70 were exposed with modified limbal incision (Group-I) and 60 with over the muscle incision (Group-II). (Table 1).

During the surgery we did not find any difficulty in approaching the extra ocular muscles in 94.5% (34 out of 36) cases with modified limbal incision, in only 2 patients we had to spend extra time in clearing and exposing the muscle. One out of these 2 also had excessive bleeding on the table. In comparison, easy access to extra ocular muscles was recorded in 80.5% cases (25 out of 31) in over the muscle incision while in 6 patients (19.5%) exposure was difficult. Two out of these 6 had excessive bleeding (Table 2). Interestingly, the suturing of the wound during the modified limbal approach was quite easy without any help from the assistant in all cases while we had to seek the help of the assistant in 54.8% (17/31) of cases in Group-II (Table 2).

Table 1: Over all view (Total No. of cases 67)

Type of squint	No of Pts	No of Recessions	No of Resections	No of Modified Limbal incisions	No of Over the muscle incisions	No of incisions
Esotropia	39	48 (9 Bil MR)	26 (4 only)	44 (2 only MR)	30 (2 only MR)	74

		recession)	recession)	recession)	recession)	
Exotropia	28	35 (7 Bil LR recession)	21	26	30	56
Total	67	83	47	70	60	130

Bil=bilateral; MR=Medial rectus; LR=Lateral rectus

Table 2: Experience during surgery (Total No. of cases 67)

During surgery	Modified limbal approach (36)	Over the muscle approach (31)
	No of Patients n (%)	No of Patients n (%)
Easy access to extraocular muscles	34 (94.5)	25 (80.6)
Excessive bleeding during surgery	1 (2.8)	2 (6.5)
Difficult suturing	0 (0)	17 (54.8)

Post operatively on day one, increased discomfort and excessive watering was complained by 13.9% patients in group-I while it was much higher (67.8% and 51.6% respectively) in Group-II. On post op examination on day one, lid swelling was noted in 5.6% in group-I and in 9.7% cases in group-II. Conjunctival redness on first post op day was very commonly seen in both groups although it was significantly less in Group-I (77.8%) as compared to patients of group-II (96.8%). No patients in both the groups required re-stitching in our series. Removal of stitches was required in 1 (2.8%) patient of Group-I and 9 (29%) patients in Group-II. One Patient (3.2%) in Group-II also developed stitch granuloma which was not recorded in any of the patients in Group-I.

DISCUSSION

Strabismus is a very common disorder in the childhood and if not treated may continue through the adulthood and old age. In majority of these patients the treatment is surgical mostly in the form of either recession or resection of extraocular muscles. Whatever adjustment is made with the muscles, these have to be exposed first. To reach the extraocular

muscle tendon and belly we have to make a window in the overlying membranes, namely conjunctiva, subconjunctival tissue and Tenon’s capsule. These three layers are very close to one another near the limbus and wide apart as we move away from it. A variety of incisions have been tried, some near the limbus³ others parallel to limbus but near the fornix⁴ and some in between these two ends (Para-limbus)⁵.

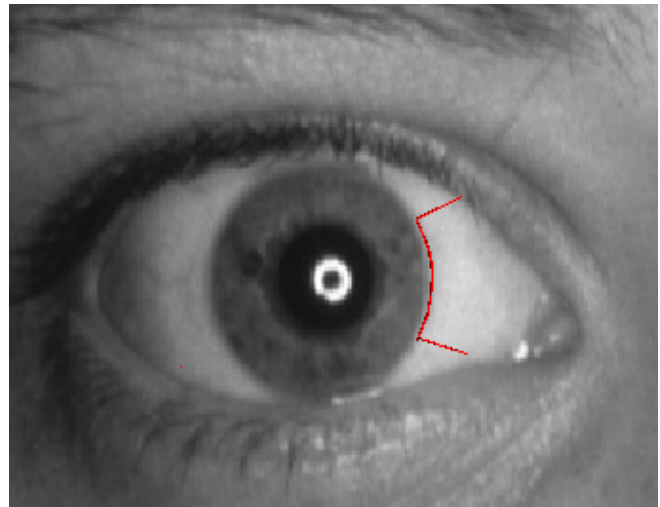


Fig 1: Diagram showing modified limbal incision

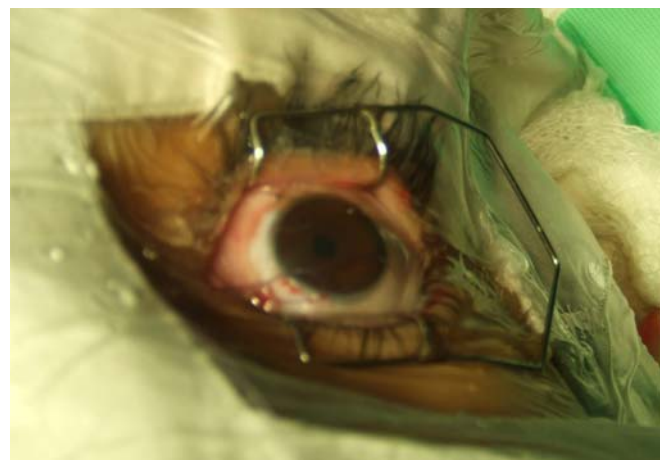


Fig. 2: Two stitch closure of modified limbal incision

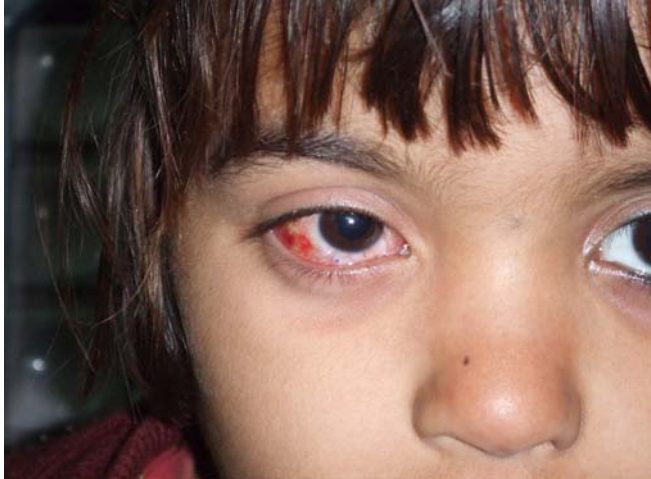

Fig 3: Post operative conjunctival redness in modified limbal approach

Table 3: Post operative comparison

Post operative problems	Modified limbal approach (36)	Over the muscle approach (31)
	No of Patients n (%)	No of Patients n (%)
Increased discomfort	5 (13.9)	21 (67.8)
Excessive watering	5 (13.9)	16 (51.6)
Lid swelling	2 (5.6)	3 (9.7)
Conjunctival redness	28 (77.8)	30(96.8)
Need for re-stitching	0 (0)	0 (0)
Need to remove stitches	1 (2.8)	9 (29)
Stitch granuloma	0 (0)	1 (3.2)

Still others have tried radial incisions⁶. We in our study used a modified limbal incision which has benefits of both limbal and radial incisions and compared it with fornix or over the muscle approach.

The Tenon's capsule also called the 'fascia of the eyeball' along with its extensions around the extraocular muscles serves as a socket in which the eye

ball can move smoothly in all directions. Its role in post operative complications has been extensively studied^{4,7,8}. Any approach which preserves the relations of Tenon's capsule and its various extensions will have minimal complications⁷. Any distortion and damage to this fascia will lead to a range of complications including marked post operative scarring. There is a good chance to reduce the scarring between conjunctiva, Tenon's capsule, muscle and sclera after surgical treatment of rectus and oblique muscles if a careful reconstruction of Tenon's capsule is made⁹.

In the present study the modified limbal incision is made at the limbus cutting sharply both the conjunctiva and the Tenon's capsule by one single snip along the limbus with two small radial cuts at its each end. The anatomy of Tenon's capsule is minimally disturbed as there is no tearing and distortion involved during exposure of extraocular muscles. This has provided us with easy access to extraocular muscles in high majority of cases with minimal complications on the operating table (Table 2) and during the postoperative period (Fig 3 and Table 3). In comparison the other incision which is made by cutting the conjunctiva and Tenon's capsule separately over the muscle itself disturbs the anatomy of the facial system as it involves tearing and shearing of this tissue in order to save the muscle from sharp cuts of scissors during its exposure. That is why 'over the muscle approach' is associated with many postoperative complications in our study (Table 3). Other researchers are convinced that "the conjunctival and Tenon's capsule incisions should not be made directly over the muscle; this will result in scarring of the muscle to Tenon's capsule or of Tenon's capsule to the muscle insertion stump, promoting restriction"⁴.

Closure of wound in this study was done with 6/0 vicryl interrupted stitches. It was in the form of just two stitches at the limbus, at junction of radial cuts with the curved part of incision in modified limbal approach (Fig 2). We never required any assistance to apply these two stitches in this incision. This is in contrast to 'over the muscle approach' where proper stitching required assistance in majority of the cases. Post operative discomfort was much less in modified limbal approach as compared to 'over the muscle approach'. Although use of fibrin glue has been advocated as an attractive alternative for closing the conjunctival incision in strabismus surgery,^{10,11} yet results of closing the wound with 6/0 vicryl in

modified limbal incision in our study were found comparable with the fibrin glue.

CONCLUSION

Modified limbal conjunctival incision for strabismus surgery is an easy and safe approach. It provides an easy access to the extraocular muscles and there are minimal postoperative complications as compared to 'over the muscle approach'. The incision only requires two stitches to re-appose its edges and there is no need to remove these stitches.

Author's affiliation

Dr. Mian M. Shafique
Associate Professor
Department of Ophthalmology
Lahore Medical & Dental College
Lahore

Dr. Nadeem H. Butt
Associate Professor
Department of Ophthalmology
Allama Iqbal Medical Colleg
Lahore

Dr Muhammad Khalil
Assistant Professor
Department of Ophthalmology
Lahore Medical & Dental College
Lahore

Dr Tayyaba Gul

Senior Registrar
Department of Ophthalmology
Lahore Medical & Dental College
Lahore

REFERENCE

1. **Callear AB, Eaqlinq EM.** "A novel conjunctival incision for horizontal strabismus surgery" *Eye*.1996; 10: 405-6.
2. **Mojon DS.** "Comparison of a new, minimally invasive strabismus surgery technique with the usual limbal approach for rectus muscle recession and plication." *Br J Ophthalmol*. 2007; 91: 76-82.
3. **Caputo AR, Guo S, DeRespinis P, et al.** "Simplified limbal incision for extraocular rectus muscle surgery." *Ophthalmic Surg*. 1991; 22: 406-8.
4. **Price RL.** "Role of Tenon's capsule in postoperative restrictions." *Int Ophthalmol Clin*. 1976; 16: 197-207.
5. **Santiago AP, Isenberg SJ, Neumann D, et al.** "The paralimbal approach with deferred conjunctival closure for adjustable strabismus surgery." *Ophthalmic Surg Lasers*. 1998; 29:151-6.
6. **Velez G.** "Radial incision for surgery of the horizontal rectus muscles." *J Pediatr Ophthalmol Strabismus*. 1980; 17: 106-7.
7. **O'Donoghue HN, Smith AB.** "Importance of Tenon's capsule in squint surgery." *Trans Ophthalmol Soc U K*. 1982; 102: 492-4.
8. **Ludwig IH.** "Scar remodeling after strabismus surgery." *Trans Am Ophthalmol Soc*. 1999; 97: 583-651.
9. **Stark N.** "Surgery of Tenon's capsule in squint operations." *Klin Monatsbl Augenheilkd*. 1992; 201: 178-80.
10. **Biender B, Rosenthal G.** "Conjunctival closure in strabismus surgery: vicryl versus fibrin glue." *Ophthalmic Surg Lasers*: 1996; 27: 976.
11. **Dedeya S, Kamleish MS.** "Strabismus surgery: Fibrin glue versus vicryl for conjunctival closure" *Acta Ophthalmol. Scand*. 2001; 79: 515-7.